PEDIATRIC NEWS

San Antonio Military Pediatric Center

Wilford Hall Air Force Medical Center
Brooke Army Medical Center
Darnall Army Community Hospital
www.sampc.amedd.army.mil

June 2003 *Volume 10 Number 3*

Housestaff Puzzler

Jennifer Geiger Capt MC
PL II
San Antonio Military Pediatric Center

A 4 year old African American male presents to the pediatric clinic secondary to fever of 103º F and ill appearance. He had three episodes of non-bloody, non-bilious emesis and two episodes of watery stool that day, with a twenty-four hour history of URI symptoms. Review of systems is significant for marked listlessness and oral refusal at home. Mom reports he had a mild limp four days prior after trauma to his left knee but has been able to bear weight and the limp has been improving each day.

His past medical history is unremarkable and his immunizations are up to date. His family history is non-contributory. He lives with both his parents and an older sibling, all healthy.

Physical exam reveals an ill-appearing, fussy but consolable child held by his mother. He is febrile to 102ºF, mildly tachycardic and hypotensive with normal oxygen saturations on room air. Head and neck exam is unremarkable except scant nasal discharge. Cardiac

Continued on page 8

In this edition

Housestaff Puzzler 1
The Ins and Outs of Blood Product Donation: Part II 1
Malrotation and Midgut Volvulus 1
Sudden Unexpected Death Due to Anomalous Coronary Artery Origin .. 10

The Ins and Outs of Blood Product Donation Part II

James Barker LTC MC
C, Pediatric Hematology/Oncology
San Antonio Military Pediatric Center

Parasitic Diseases

Malaria — Transfusion-transmitted malaria is common in some parts of the world but is rare in the United States, occurring at an estimated rate of 0.25 cases per million donated units for 1972-1988 and zero to 0.18 cases per million units transfused from 1993 through 1998. Policies for preventing such transmissions rely on donor questioning during the health history interview.

The deferral criteria for malaria are:

· Donors with a history of malaria are deferred for three years after becoming asymptomatic.

· Travelers to a malaria endemic area are deferred for one year after their return to the United States (provided they have not had malarial symptoms).

· Immigrants from or residents of malarial endemic countries are deferred for three years after their departure from the endemic country based upon the premise that such individuals may have partial tolerance to malarial parasites, thereby resulting in the delay of malarial symptoms beyond one year.

Continued on page 2

Malrotation and Midgut Volvulus

Tiffany Anthony and Christopher Breuer
PL3 Resident in General Surgery/ Chief of Pediatric Surgery, WHMC

Introduction

The term malrotation refers to a condition in which the midgut, that part of the intestine supplied by the superior mesenteric vessels extending from the duodenojejunal flexure to the mid transverse colon, remains unfixed and suspended on a narrow-based mesentery. Malrotation can result in midgut volvulus which, at best, is diagnosed early with rapid surgical intervention and minimal morbidity and mortality and, at worst, results in rapid

Continued on page 4

Continued from page 1

A June 2000 FDA draft guidance document has proposed a revision of the malarial donor screening criteria for immigrants from or residents of malarial endemic countries. Residents are defined as those living in the region for at least five years. In addition to a three-year deferral after arrival in the United States, these persons would also be deferred for three years after their last visit to a malarial endemic region, due to the possibility that partial acquired immunity to malaria could delay the occurrence of malarial symptoms.

In a retrospective review of transfusion-transmitted malaria in the United States from 1963 through 1999, there were 93 cases reported to the Centers for Disease Control and Prevention; ten of the 93 patients died. Among the donors for whom complete information was available, 62 percent would have been excluded from donating according to current guidelines or those in place at the time of donation.

Chagas' disease and Babesiosis

For Chagas' disease and babesiosis, which have rarely been reported to be transmitted by blood transfusion in North America (five cases of Chagas, fewer than thirty cases of babesiosis), donor questioning is restricted to asking donors whether they have ever had either one of these diseases.

Creutzfeldt-Jakob Disease

Creutzfeldt-Jakob disease (CJD) is a rare, fatal, degenerative neurologic disorder with a long asymptomatic latent period; it is thought to be caused by a prion. CJD has been transmitted from human to human by the transplantation of dura mater, by corneal transplantation in a single case, by the injection of pituitary derived human growth hormone, and by the reuse of EEG electrodes.

There are no reported cases of transmission of CJD by blood transfusion, and epidemiologic studies have not provided any evidence for such transmission. Nevertheless, due to the long incubation phase of the disease (as demonstrated from growth hormone transmissions) and the inability of conventional sterilization methods to inactivate the organism, the theoretical risk of CJD transmission from asymptomatic donors to recipients of blood components or plasma derivatives cannot be ruled out.

Variant Creutzfeldt-Jakob disease

Variant Creutzfeldt-Jakob disease (vCJD) is a fatal, degenerative neurologic disease newly discovered in the United Kingdom in 1996. As of July 2001, over 100 definite or probable cases have been reported in the United Kingdom, with two reported elsewhere but assumed to be acquired in the UK, and an additional three cases originating in France. The etiologic agent of vCJD (probably a prion) is the same agent that causes bovine spongiform encephalopathy (BSE, "mad cow disease"). No cases of transfusion-transmitted vCJD have been reported anywhere in the world. However, vCJD and classic CJD are significantly different illnesses, particularly in the age at the onset of symptoms and the rapidity of neurologic deterioration. Thus, the absence of transfusion-transmitted classic CJD does not exclude the possibility that vCJD might be transmitted via transfusion.

Blood donor deferral — To eliminate possible risk to transfusion recipients of developing CJD, the FDA has recommended that all prospective blood donors who have received human pituitary derived growth hormone, a dura mater transplant, or have a family history of CJD in a blood relative be permanently deferred.

Since virtually all reported vCJD cases have occurred in the United Kingdom, deferral of donors who have traveled to the United Kingdom during the peak period of exposure to BSE infected cattle (1981 to 1996) was deemed by the FDA to be a means of reducing the hypothetical risk of transmission of vCJD through transfusion. In an attempt to balance increased safety against decreased blood availability, the FDA adopted a policy, effective April 2000, that a donor is indefinitely deferred if he/she spent six months or more in the United Kingdom (UK) from 1980 through 1996. In addition, donors are deferred if they have injected insulin from a bovine source. Questions have been added to the donor interview to elicit this information.

The Transmissible Spongiform Encephalopathy Advisory Committee, an advisory committee to the FDA, voted to further tighten these restrictions, and a draft revised guidance to the blood industry was issued by the FDA on August 27, 2001. Under the proposed revised guidance, to be implemented by May 31, 2002, donors will be deferred who:

- Have spent > 3 cumulative months in the UK from 1980-1996, or
- Have spent >5 cumulative years in France from 1980-present, or
- As current or former US military personnel, civilian military employees and their dependents, have lived for > 6 months at US military bases in Northern Europe from 1980-1990 or elsewhere in Europe from 1980-1996, or
- Received a blood transfusion in the UK between 1980-present
- For implementation by October 31, 2002, donors will be deferred who have spent a

cumulative total period of > 5 years in Europe from 1980 to the present.

·The American Red Cross has gone beyond these recommendations. Updated information on this evolving subject can be found on the websites of the American Red Cross <www.redcross.org> and the Food and Drug Administration <www.fda.gov>.

Bacterial Infection

Bacterial infection is another potential fatal complication of transfusion. Bacteria can be introduced into the donor unit at the time of collection if the donor is bacteremic, if the skin site is not properly decontaminated, if there is an undetected abscess adjacent to the phlebotomy site, or through introduction of a small skin plug in the phlebotomy needle. Examination of the skin at the venipuncture site is conducted before phlebotomy and strict requirements for assuring the sterility of the site are adhered to by the phlebotomist. Blood is not collected from persons who are febrile at the time of donation, who state that they do not feel well, or who are taking systemic antibiotics.

These requirements are also applied to candidates for autologous donation, since cases of transfusion-induced sepsis in autologous recipients have occurred due to the ability of Gram negative rods to multiply at refrigerator temperatures and secrete endotoxin into the blood bag. Autologous donors who are taking antibiotics or who give a history of recent or concurrent medical procedures are evaluated for the possibility of bacteremia and deferred accordingly.

Other Recipient Safety Issues

History of Malignancy in Donor

Donors with a history of malignancy pose a theoretical risk to recipients; however, no cases of transfusion-transmitted malignancy have been reported. Since many transfusion recipients are immunosuppressed, it may be theoretically possible that malignant cells circulating in a donor's blood could engraft and multiply in a recipient, provided there was a sufficient degree of genetic matching. In order to decrease the possibility of this occurrence, donors are questioned about a history of cancer.

In most blood centers, a donor with a history of a solid organ tumor will be deferred and will be eligible to donate only if he/she has been symptom-free and considered to be clinically cured for a defined time period, usually five or ten years. Donors with a history of hematologic malignancy are permanently deferred; in comparison, donors with specific malignancies (eg, basal cell cancer of skin, cervical carcinoma in situ) that have been fully excised are not deferred, since the tumor is known to be low grade and not capable of hematogenous spread.

Medications taken by donor

Most medications taken by donors pose no known risks to recipients. In most cases, only small quantities of drugs are present in a unit of blood and the drugs will undergo significant dilution in the recipient's plasma volume. However, some drugs may pose a risk due to their demonstrated teratogenic potential at low plasma concentrates. Four such medications (all in FDA pregnancy category X) have been identified by the FDA as potentially dangerous to recipients: these are etretinate (Tegison) used for severe psoriasis, acitretin (Soriatane) also used for severe psoriasis, isotretinoin (Accutane) used for severe cystic acne, and finasteride (Propecia, Proscar) used for symptomatic benign prostatic hypertrophy and hair regeneration. Deferral periods are one month for isotretinoin and finasteride, three years for acitretin, and permanent for etretinate due to its demonstrated presence in plasma several years following cessation of use.

Protection of the Donor

Donors are asked questions concerning a history of cardiovascular, pulmonary, liver, or other severe disease. In general, donors with coronary artery disease, cardiac valvular disease, arrhythmia, significant cerebrovascular disease, or congestive heart failure are deferred, as are donors with any active pulmonary disease impairing gas exchange.

·Donors who have undergone recent surgery in the absence of blood transfusion are deferred until healing is complete and full activity has been resumed.

·Donors who are pregnant are deferred during pregnancy and for six weeks after delivery.

·Donors with seizure disorders are acceptable provided that they have had no seizures within the past 12 months with or without medications. This policy appears reasonable since there are no data linking the convulsive activity associated with seizure disorders to the convulsive activity that may occur secondary to ischemia from a postdonation vasovagal reaction.

The minimal age for donation is legally established by individual states in the United States and is generally 17 or 18; donors who are legally minors need written consent of a parent or guardian. The upper age for blood donation has changed over the past decade, following studies documenting that individuals over the age of 65 who met all other donation criteria had no greater frequency of severe or life-threatening reactions and had lower rates of posttransfusion reactions than younger donors. Most blood centers no longer impose an upper age limit for donor eligibility.

Continued from page 1

decompensation and death.

History

Information on failure of rotation and fixation of the intestinal tract has accumulated slowly. Before 1900, only descriptions from surgery or autopsy were reported. These descriptions could not be placed in context until the embryology was understood. The first meaningful description of the embryology was written in 1898 by Mall, Professor of Anatomy at Johns Hopkins. He was able to describe the rotation and fixation of the bowel through the use of reconstructed embryos. In 1923, Dott published "Anomalies of intestinal rotation: Their embryology and surgical aspects." This classic paper correlated clinical observations to their underlying embryology. In 1936, Ladd wrote the key article on the treatment of this condition. Ladd's description of the release of the duodenum and placement of the cecum in the left upper quadrant remains the definitive surgical treatment for nonrotation with midgut volvulus.

Embryology

Normal bowel rotation begins during the fourth week of gestation and is complete by the end of the first trimester. Fixation of the bowel extends until near term. An understanding of this process is imperative to understanding anomalies of bowel rotation. The intestinal tract develops as a single tube consisting of the foregut, midgut and hindgut. Two distinct processes are required for normal bowel rotation. Simultaneously, the duodenojejunal loop and the distal cecocolic loop rotate 270 degrees counterclockwise and become fixed in their normal anatomic positions in the retroperitoneum.

The duodenojejunal loop lies above or anterior to the superior mesenteric artery. This loop first rotates counter-clockwise 90 degrees to the right of the artery and then another 90 degrees under the artery. Finally, the loop rotates another 90 degrees across the spine and upward. This establishes the position of the duodenojejunal junction on the left side of the spine, level with the duodenal bulb. This junction becomes the ligament of Treitz.

The cecocolic loop originally hangs beneath the superior mesenteric artery. Rotation also occurs in a counter-clockwise direction. First, the loop moves to the left of the superior mesenteric artery approximately 90 degrees. Then the loop proceeds above the artery 90 degrees. A final movement to the right and downward 90 degrees establishes the typical inverted U-shaped configuration of the colon.

Whereas rotation of the bowel occurs by the end of the third month of gestation, fixation to the retroperitoneum occurs gradually until term. Normal fixation to the retroperitoneum results in a wide mesenteric base from the ligament of Treitz to the cecum. This wide mesenteric base is resistant to volvulus. The duodenojejunal loop achieves fixation to the retroperitoneum shortly after rotation. The cecocolic loop is fixed to the retroperitoneum in a much slower time course, extending to near term. This embryology explains the observation of infants with mobile or high cecum.

Incidence

The true incidence of malrotation is difficult to estimate because some patients remain undiagnosed. Approximately 50-60% of cases are encountered in the first month of life and 30- 40 % of these within the first week of life. Nearly 90% are diagnosed by one year of age. It is generally accepted that once the diagnosis of malrotation has been established, surgical correction is mandatory to prevent the development of volvulus, which occurs in 40-50% of cases not treated surgically.

Classificationof the Abnormalities of Intestinal Rotation

A spectrum of abnormalities of intestinal rotation exists. The term malrotation really refers to all abnormalities of intestinal attachment. Malrotation can be divided into nonrotation, incomplete rotation, and incomplete fixation. Nonrotation refers to lengthening of the bowel on the superior mesenteric artery (SMA) axis with essentially no rotation. The clinical manifestation of nonrotation is usually midgut volvulus. Incomplete rotation occurs when there is partial rotation of the bowel about the SMA axis but no complete rotation. Clinical manifestations of incomplete rotation include midgut volvulus, duodenal obstruction, and reverse rotation (internal hernia). Incomplete fixation refers to the failure of descent of the cecum and fixation of the mesenteries. The clinical manifestations of incomplete rotation include internal hernia (mesocolic) and cecal volvulus.

Associated Anomalies

As many as 50% of patients with malrotation will have other associated anomalies. Duodenal atresia is one of the more common findings, and partially obstructing duodenal webs must not be overlooked in infants with malrotation. Frequently, these infants will have the classic double bubble on plain radiograph.

Malrotation is also an integral part of congenital diaphragmatic hernia and abdominal wall defects. Congenital diaphragmatic hernias, omphalocele, and gastroschisis all

have obligate varying degrees of nonrotation depending on the extent of intestinal displacement outside the abdomen. Malrotation associated with CDH, gastroschisis, or omphalocele is generally not corrected at the time of operation for these defects. The infants are however still at risk for future volvulus.

Malrotation has been associated, albeit rarely, with jejunoileal atresia and Hirschsprung's disease, and intussception. Mesenteric cysts have been found with malrotation, but whether this is primary or results from lymphatic obstruction in chronic volvulus is not clear.

CLINICAL PRESENTATION

With normal rotation, the mesentery is broad-based and fixed, but the narrow pedicle formed by the base of the mesentery in malrotation predisposes the midgut to clockwise twisting from the duodenum to the transverse colon. Various clinical presentations ranging from acute midgut volvulus with ischemic bowel injury to chronic abdominal pain may result from failure of normal intestinal rotation and fixation.

Acute Midgut Volvulus

The majority of patients with acute midgut volvulus are infants; in fact most present in the first month of life. In the first week of life, 30% will present; over 50% will present in the first month.

The primary presenting sign of malrotation is the sudden onset of bilious vomiting in a previously healthy, growing infant. Vomiting is present in 95% of cases and is almost always bilious, but can be bloody if there is intestinal necrosis. Abdominal distention is present in 56% of patients, and stools have gross blood in 28%. Abdominal pain and tenderness are also frequently present, especially with bowel ischemia. Neonates generally appear ill, with decreased capillary refill in the extremities and grunting respirations. Without appropriate diagnosis, resuscitation, and surgical intervention, the infant will rapidly progress to dehydration, lethargy, acidosis, and profound shock.

In patients with acute midgut volvulus, plain radiographs are not used for definitive diagnosis, but may reveal a gasless abdomen or dilated bowel suggesting obstruction. Occasionally there may be evidence of duodenal obstruction with a double bubble sign. Unfortunately, these films may be deceiving and look normal. The clinical presentation of bilious vomiting, bloody stools, lethargy, and peritoneal findings, along with plain films that do not show pneumatosis indicating necrotizing enterocolitis, necessitates immediate laparotomy to prevent the loss of significant amounts of bowel. The outcome for midgut volvulus is time dependent, which is the fundamental reason that signs and symptoms of neonatal intestinal obstruction must be pursued aggressively until a definitive diagnosis is obtained. If the diagnosis is in doubt, and there are no clinical signs of bowel ischemia, then most pediatric surgeons would proceed with an upper gastrointestinal series to demonstrate duodenal obstruction or failure of duodenal rotation across the midline with fixation of by the ligament of Treitz. Ultrasonography can also be used to demonstrate malrotation. Color doppler image shows the abnormal position of the superior mesenteric vein (SMV) to the left of the superior mesentery artery (SMA).

Chronic Midgut Volvulus

Intermittent or partial midgut volvulus (chronic midgut volvulus) is less frequent than acute volvulus. It is more commonly encountered in children older than 2 years of age. Recurrent abdominal pain and malabsorption are the two primary presentations of chronic midgut volvulus. In infants and children older than 1 month of age, intermittent bilious vomiting is present in 30%, with colicky abdominal pain in 20%. Some of these patients present with failure to thrive, chronic malabsorption, and diarrhea. The pathophysiology behind the malabsorption and failure to thrive is based on the fact that chronic midgut volvulus results in lymphatic and venous obstruction with enlargement of the mesenteric lymph nodes. Absorption and nutrient transport are impaired by the venous and lymphatic stasis, leading eventually to protein-calorie malnutrition.

Again, a history of bilious emesis demands an immediate upper gastrointestinal series. However, in patients without bilious emesis, an upper GI series is usually obtained as part of a work-up for chronic abdominal pain or failure to thrive. Surgery is indicated in all patients with the findings of malrotation, and a significant number of these patients will have postoperative resolution of symptoms.

Asymptomatic Malrotation

The incidental finding of malrotation on radiography or at surgery raises the question of the eventual risk for complications in an asymptomatic patients. There has been some historical controversy on this indication for a Ladd's procedure. The current consensus is that corrective surgery is indicated at any age, but particularly in asymptomatic infants younger than 2 years of age who are at high risk for eventually developing a volvulus.

The first indication of malrotation may be found during surgical exploration for an acute abdomen. Locating an acutely inflamed appendix in a patient with malrotation may be anticipated by radiographic absence of a cecal shadow

in the right lower quadrant. Generally, the appendectomy should be performed and a follow-up formal upper gastrointestinal series performed after recovery from emergency surgery. If the upper GI study demonstrates malrotation, then corrective surgery should be undertaken.

Imaging

An upper gastrointestinal series is the definitive imaging modality for diagnosing malrotation. Contrast should proceed from the duodenal bulb across the spine and then downward. The third portion of the duodenum should cross back to the left side of the spine, making the duodenal C-loop. The fourth portion of the duodenum should ascend to the level of the greater curvature of the stomach. This is the ligament of Treitz, and it is frequently at approximately the same level as the duodenal bulb. Any deviation from this radiologic appearance suggests a possible rotational abnormality. More overt diagnostic findings are obstruction of the duodenum, abnormal right-sided position of the ligament of Treitz, and the filling of jejunal loops on the right side of the abdomen.

Ultrasound is a very rapid diagnostic test for defining vascular flow through the superior mesenteric vessels. There is a characteristic "whirlpool" flow pattern of the superior mesenteric vessels with volvulus. The abnormal position of the superior mesenteric vein (SMV) to the left of the superior mesenteric artery (SMA) can be seen on US. A fluid-filled duodenum and dilated thick bowel loops are also indicators of malrotation with volvulus. Experienced ultrasonographers can exclude malrotation by demonstrating normal rotation of the C-loop relative to the SMA and SMV.

A barium enema is generally not helpful in the diagnosis of malrotation and midgut volvulus and may add harmful delay. The relevance of plain films has been discussed previously.

Preoperative Management

Infants and children with midgut volvulus may require aggressive resuscitation. Those with a significant vomiting history are frequently at least 10% to 15% dehydrated. Rapid resuscitation with crystalloid is indicated. Prolonged resuscitation efforts, however, are unwarranted because expeditious laparotomy is essential, and ultimately survival is dependent on it. Temperature regulation is imperative. Nasogastric decompression should be started, and Foley catheter should be placed. Broad-spectrum antibiotics are given. Central venous pressure monitoring and arterial lines will aid in resuscitation. However, they should not delay movement to the operating theatre and initiation of the laparotomy. Strong consideration should be given to an anticipated period of postoperative ventilatory management.

Operative Technique

Operative repair of malrotation is achieved nearly universally using the procedure described by William E. Ladd and which bears his name. The Ladd procedure corrects the fundamental abnormalities associated with malrotation with or without midgut volvulus. The standard operative approach is a right upper quadrant transverse incision. A midline laparotomy can be used in older patients. The Ladd procedure consists of the following four important steps, which must be carried out in proper sequence. Following abdominal entry and rapid exploration, (1) the bowel is eviscerated through a generous incision and inspected for volvulus. With volvulus, (2) the gut is derotated in a counterclockwise fashion. If there is ischemic gut, a period of intraoperative warming and observation is necessary. After an adequate period of time, bowel viability should be assessed with both Doppler and infused with fluorescein if necessary. Situations with clearly demarcated intestinal necrosis require sound surgical judgment and surgical options include bowel resection, stomas, or a second look operation. The guiding principle in questionable bowel viability is the preservation of maximal bowel length.

If the bowel is viable then, (3) the Ladd's bands are divided. The Ladd's bands generally extend from the retroperitoneum in the right upper quadrant across the duodenum and the proximal mesentery. These peritoneal folds usually tether across the cecum ascending colon, duodenum, and right lateral gutter. The bands are carefully incised along the medial aspect of the duodenum. The underlying tissue of the anterior leaf of the mesentery is divided, exposing the superior mesenteric artery. This allows the ascending colon and duodenum to be separated, widening the base of the mesentery. Eventually, with complete lysis, the cecum and ascending colon lie on the left side of the abdomen. The duodenum and proximal jejunum should now lie in a straight line down the right gutter, and the ileocecal junction should be placed on the opposite side of the abdomen, with the small bowel resting below in a U shape. The mesentery should be free from any constricting bands at its base. The fourth and final step of the Ladd's procedure is the appendectomy. Usually an inversion appendectomy is performed. Without an appendectomy, the appendix is in the left upper quadrant and presents an unnecessary, potential diagnostic challenge with the onset of appendicitis.

If there has been significant ischemia and reperfusion, the small bowel may swell and ascites may develop, leading to abdominal

compartment syndrome. The end-result is further compression of recovering bowel or marginally ischemic bowel. Significant attention must be directed to this potential complication, and judgment at the time of closure should prompt a construction or placement of a Silastic silo in infants and a temporary mesh closure in older patients.

Postoperative management

There are several important postoperative considerations. First, as previously mentioned, significant midgut volvulus with prolonged ischemia, there will be severe bowel edema and resulting third space fluid loss. There may also be ascites. Close attention should be paid to postoperative resuscitation. Also, all efforts for intestinal decompression should be maintained. Nasogastric decompression as well as abdominal decompression with Silo or mesh closure are important. Intestinal viability can be checked through the Silo or mesh closure. Prompt re-exploration with resection of ischemic intestine should be performed at second-look procedures within the first 48 hours. With assured intestinal viability and resolution of the inflammatory response and secondary edema, abdominal closure can be considered.

Post-operative feeding may be problematic as bowel suffering reperfusion injury will be compromised further with enteral feeding and may result in transmural ischemia. This transmural ischemia of the intestine will lead to mucosal sloughing, resulting in decreased barrier function, translocation, and progressive sepsis. Early enteral feeding should not be attempted. The unfortunate but life saving need for total parental nutrition early in the postoperative course may be the only choice. Patients with significant bowel loss and resulting short bowel syndrome will require prolonged TPN.

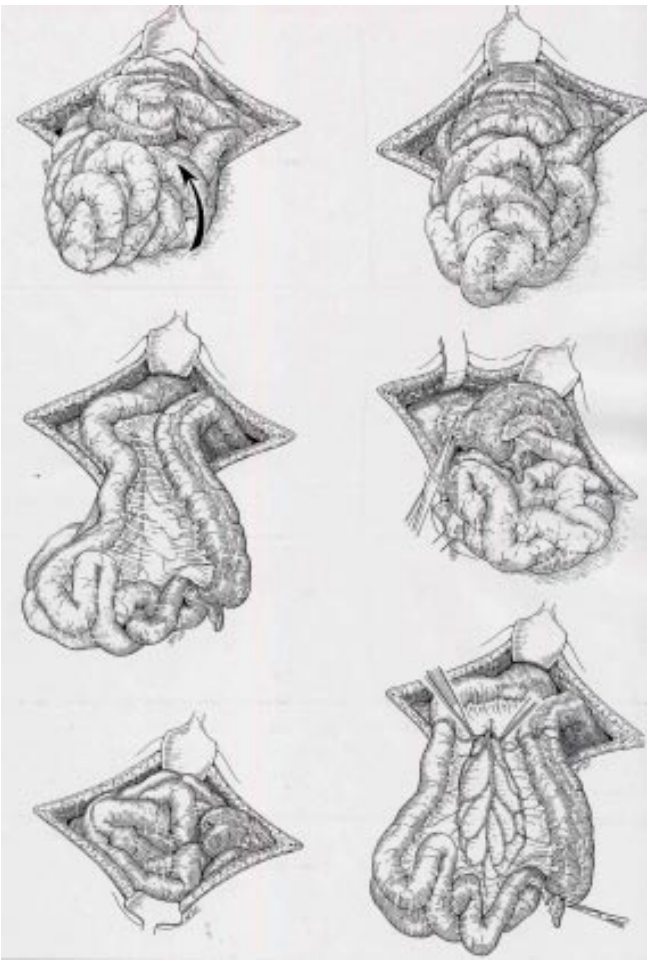

Outcomes

Surgery is very successful. In Ladd's 1941 clinical summary, 8 of 35 patients with malrotation who underwent surgery died. However, all of the surviving 27 were relieved of symptoms and there was no recurrence of the obstruction or volvulus. Contemporary results after surgical correction of malrotation are generally excellent with normal life expectancy in the absence of compromised bowel at the time of the initial procedure. Currently, the mortality rate for the operative correction of malrotation ranges from 3 to 9% overall. There is only a 5% or lower chance of recurrent volvulus or bowel obstruction.

Resources

Ladd WK: Surgical diseases of the alimentary tract in infants. N Engl J Med 1936;215:705.

Mall FP: Development of the human intestine and its position in the adult. Bull Johns Hopkins Hosp 1898;9:197.

O'Neill JA, Rowe MI, Grosfeld JL, et al: Pediatric Surgery, 5th ed. St. Louis, CV Mosby, 1998, pp 1199-1213.

Bland KI, Sarr MG, Cioffi WG, et al: The Practice of General Surgery, Philadelphia, WB Saunders Company, 2002, pp 918-922.

Spitz L, Coran AG: Rob & Smith's Operative Surgery Pediatric Surgery, 5th ed. New York, Chapman & Hall Medical,1995, pp 341-347. (picture adapted from atlas)

Continued from page 1

exam is remarkable for sinus tachycardia without murmur, rub or gallop. Lungs are clear bilaterally without increased work of breathing. Abdominal exam is noted to be soft without masses or hepatosplenomegaly. His extremities are warm with capillary refill less than two seconds. He has a slightly antalgic gait favoring the left leg. Exam reveals mild tenderness to palpation over the distal femur but no swelling, erythema or deformity.

Laboratory evaluation includes the following. Complete blood count (CBC) is significant for a WBC of 17,000 with 61% segmented neutrophils and 33% band forms. Erythrocyte sedimentation rate is 25. Urinalysis reveals a specific gravity of 1.021, pH of 5.0, positive leukocyte esterase with 50 WBC/hpf. Cultures of the throat, blood, stool and urine are obtained. Rapid EIA for Influenza A/B and Rotavirus antigen are negative. His chest radiograph is without focal infiltrate. Radiograph of his left femur is negative for soft tissue edema, air or fracture. He received intravenous ceftriaxone and a total of 60cc/kg normal saline in the clinic and is admitted to the ward secondary to concerns of sepsis and volume depletion. Over the next twelve hours he develops a diffuse pruritic, erythematous, macular rash over his trunk and extremities. He remains tachycardic with heart rate in the 160s and hypotensive with systolic blood pressures in the 70s to 80s and diastolic blood pressures in the 30s to 40s despite continued fluid resuscitation. He initially remains alert and responsive, but approximately twelve hours after admission becomes increasingly lethargic with delayed capillary refill. He is then transferred to the PICU for concerns of septic versus toxic shock. Central and arterial lines are placed. Antibiotic therapy is changed to cefipime (150mg/kg/day) and clindamycin (40mg/kg/day). Intravenous immunoglobulin (IVIG) at 2mg/kg is given after blood is drawn for further laboratory evaluation. Blood gas is significant for pH 7.29, CO_2 32, O_2 105, HCO_3 15 with base deficit of 10. Sodium bicarbonate therapy is initiated to treat acidosis. Fluid resuscitation is continued with albumin and crystalloid. Eventually a dopamine continuous infusion is started to maintain acceptable blood pressure. Serology obtained prior to administration of IVIG includes cytomegalovirus, Epstein-Barr Virus, rocky mountain spotted fever (RMSF), leptospirosis, ehrlichiosis, and typhus. Serum streptozyme is sent. Viral stool cultures are obtained. Repeat CBC is significant for WBC of 10.4 (no differential obtained), hemoglobin 9.4, hematocrit 29 and platelets of 153,000. Over the next eight hours he develops grunting respirations. Chest radiograph confirms pulmonary edema without significant effusion. He is electively intubated secondary to increased work of breathing. An echocardiogram demonstrates good contractility without evidence of pericardial effusion or vegetations. He subsequently develops DIC approximately eighteen hours after admission requiring infusion of fresh frozen plasma. He remains febrile throughout the acute illness. He begins to improve and is extubated after forty hours. He is weaned off dopamine after forty-eight hours. On hospital day three, the macular rash begins to desquamate around his lips, hands, buttocks and inguinal region. He becomes afebrile on hospital day four but continues to have an elevated WBC at 36,000 with 39% neutrophils and 29% band forms. ESR remains mildly elevated at 31. He is transferred back to the ward on hospital day six. On hospital day seven he develops pain and swelling of the left knee with refusal to walk. He remains afebrile. Bone scan of the left knee reveals increased enhancement over the left femoral condyle. MRI is obtained secondary to concerns of joint involvement and shows a small fluid collection overlying the prepatellar bursa without intra-articular involvement. An orthopedic consult is obtained. His prepatellar bursa is aspirated with return of purulent fluid. Gram stain reveals gram-positive cocci in clusters. Culture grows *Staph aureus*. He is taken to the OR for drainage and exploration of the bursa with no further extension of infection noted. The bursa is thoroughly irrigated and closed. The isolate was later determined to produce toxic shock syndrome toxin 1 (TSST-1). A PICC line is placed and he is sent home on oxacillin to complete a 21-day course. On follow up visits, he is clinically well with resolution of limp.

Toxic shock syndrome (TSS) is an acute febrile illness leading to multi-system dysfunction caused by one or more exotoxin producing bacteria. It is uncommon in prepubertal children but has been reported even in infants. The most common pathogens include *Staph aureus* and group A Streptococcus. There is a wide range of initial presentations that must be recognized to establish timely and aggressive management of these challenging patients. During the early 1980s, TSS was linked to high absorbency tampon use in young women. Because of this, tampon manufacturers decreased the absorbency of the tampons and changed their chemical composition. The brand most associated with TSS was removed form the market by the manufacturer. Non-menstrual TSS is now becoming increasingly more recognized from a wide variety of etiologies. The definition of toxic shock syndrome was established by the Centers for Disease Control and Prevention (CDC) to include six criteria. The major criteria include temperature greater than or equal to 102°F, diffuse rash with desquamation 1-2

weeks after the onset of illness, and hypotension. In addition, multi-organ dysfunction in three or more systems (gastrointestinal, muscular, mucous membranes, renal, hepatic, hematologic and central nervous system) are the basis for diagnosis. If obtained, results must be negative for blood, throat or urine culture (except blood for *Staph aureus* or GABHS) and serologies for RMSF, leptospirosis or measles. If five of the six criteria are established, a probable diagnosis can be made. There are several exotoxins linked with causing TSS. These include TSST-1, the staphylococcal enterotoxins and the streptococcal pyrogenic exotoxins. These toxins interact with the major histocompatability complex class II molecules on antigen presenting cells leading to the release of various cytokines causing the aforementioned clinical picture. These include tumor necrosis factor (TNF-a) and interleukin-1 (IL-1). Other effects include enhanced delayed hypersensitivity reaction, decreased production of immunoglobulin, and induction of fever. Initial presentation of TSS from any cause is similar. Patients first develop a prodrome of malaise, headache, vomiting and diarrhea. Then, a diffuse, erythematous, blanching rash appears with spread to the extremities. Usually within 24-48 hours, the patient develops tachycardia, tachypnea, hypotension and oliguria with onset of a severe shock state. The most profound symptom of TSS is hypotension. This is likely due to vascular leak and decrease in vasomotor tone causing pooling of blood in the peripheral vasculature and generalized peripheral edema. Multi-system organ dysfunction then develops secondary to decreased tissue perfusion leading to ischemia. Patients may develop acute renal failure, adult respiratory distress syndrome requiring mechanical ventilation, cardiac dysfunction and disseminated intravascular coagulation. Treatment of TSS should take place in a pediatric intensive care unit where invasive monitoring and support are available. The cornerstone of therapy is patient stabilization and supportive care. Aggressive fluid resuscitation is essential. Support of blood pressure with ionotropic agents may be necessary in patients with inadequate response to fluid management. Invasive monitoring of blood pressure and central venous pressure as well as urine output is important to ensure adequate resuscitation. A search for the cause of infection should ensue and is not always obvious. Non-menstrual etiologies include pneumonia, lymphadenitis, osteomyelitis, and cutaneous and subcutaneous infections. Surgical wound infections, abscesses and sinusitis with nasal packing after ENT procedures are also important causes. Removal of any potentially causative foreign body is important, as well as drainage of an abscess if present. Empiric antibiotic therapy with an anti-staphylococcal penicillin (or if concern for MRSA with clindamycin or vancomycin) likely does not alter the course of TSS but will treat causative infection and possibly decrease the risk for recurrent TSS. In many cases, clindamycin is added to the b-lactam antibiotic in the attempt to decrease the toxin production by the bacteria. Cultures should be obtained from any potential site prior to the initiation of the antimicrobial therapy. A somewhat controversial addition to the therapy includes the use of IVIG. Of note, in the general population the prevalence of antibodies to TSST-1 is 70% at 10 years of age, 88% at 20 years and greater than 95% during adulthood.[1] In almost all patients with TSS, pre-existing antibody to TSST-1 is non-existent or low.[1] IVIG has been shown in vitro and in vivo to neutralize these toxin antigens thought to cause the clinical manifestations of TSS. There have been several case reports and anecdotal evidence that the use of IVIG improves morbidity and mortality of TSS. Furthermore, a case series of twenty-one patients with streptococcal TSS treated with one dose of 2g/kg IVIG at Mount Sinai Hospitals in Toronto, Canada demonstrated a 33% decline in mortality in the treated patients.[2] Although there are no double blinded, randomized controlled trials involving the treatment of TSS with IVIG due to the difficulty of such a study with such an uncommon entity, there is strong evidence to suggest its usefulness. In severe TSS refractory to the above therapies, there have been a few case reports showing benefit from plasmapheresis. One case involved a 29 year old woman with severe TSS leading to cardiovascular collapse and imminent death. The patient was treated with plasmapheresis in which one third of her blood volume was replaced with fresh frozen plasma.[3] She subsequently improved and made a full recovery after a prolonged ICU course. Finally, some experts recommend the use of corticosteroids in refractory cases.[4] Toxic shock syndrome although uncommon in pediatrics remains a difficult entity to treat. A high index of suspicion is necessary to ensure timely initiation of intensive supportive care and treatment. With prompt intervention, mortality in pediatric patients is now likely less than 5% of cases of TSS. Mortality and morbidity are likely to continue to improve with the advent of more novel therapies.

General References**:**

Todd, James K. Toxic Shock Syndrome. Principles and Practice of Pediatric Infectious Diseases, 2nd ed. New York, Churchill Livingstone, 2003.

Tapiero B. and Lebel M. Toxic

Shock Syndrome. Pediatric Infectious Diseases: Principles and Practice. New York, Appleton and Lange, 1995.

References:

1. Schlievert PM. Use of intravenous immunoglobulin in the treatment of staphylococcal and streptococcal toxic shock syndromes and related illnesses. *J All Clin Imm* 2001; 108.
2. Kaul R, et al. Intravenous Immunogloblin Therapy for Streptococcal Toxic Shock Syndrome – A Comparative Observational Study. *CID* 1999; 800-7.
3. Hoeper MM, et al. Plasmapheresis in Streptococcal Toxic Shock Syndrome. *Crit Care Med* 2001; 29.
4. Todd JK, Ressman M. Caston SA, et al. Corticosteroid therapy for patients with Toxic Shock Syndrome. *JAMA* 1984; 252: 3399-3402.

Sudden Unexpected Death Due to Anomalous Coronary Artery Origin

James Feig M.D.
Forensic Pathologist
Wilford Hall Medical Center

Case Report

A four year old black male began complaining of a headache and dizziness during evening playtime. The mother noted a fever (temperature = 103.0°F). The child subsequently reported feeling better after receiving Tylenol and asked for something to eat. However, he soon began vomiting and then became lethargic. The unconscious child was transported to the hospital via EMS and was pronounced dead a short time later. The patient had an unremarkable prepartum course and his medical history was significant only for a physiologic heart murmur. There was no pertinent family history of disease. Clinically, infectious meningitis was suspected.

Due to the unexplained, sudden nature of the death a forensic autopsy examination was conducted. The external examination revealed a clean, healthy appearing child without evidence of injuries or rashes. At autopsy, the brain was unremarkable with glistening, nonpurulent meninges. A postmortem CSF culture was negative. However, examination of the heart revealed that both coronary ostia were located in the right sinus of Valsalva (ordinarily the left main arises from the left sinus of Valsalva). See figure. The left main then passed between the roots of the pulmonary artery and aorta before branching into the left anterior descending and circumflex arteries. Additionally, the lungs were noted to be congested and heavy without grossly visible consolidated areas. Subsequent microscopic examination of the lungs revealed early, acute bronchopneumonia in a patchy, bilateral distribution. A postmortem blood culture was positive for Streptococcus pneumoniae growth. There were no other significant findings at autopsy and toxicological analysis was negative.

Discussion

The most significant revelation at autopsy was the finding of an unsuspected congenital anomaly of coronary artery origin. In this case, the left main aberrantly arose from the right aortic sinus (right sinus of Valsalva) adjacent to the origin of the right coronary artery and then passed between the pulmonary artery and the root of the aorta in order to perfuse the left side of the heart.

Historically, anomalies of coronary artery origin from the aorta have been largely relegated as curiosities found at the time of autopsy with little clinical significance. Anomalies with more obvious functional consequences such as origins from the pulmonary artery, leading to almost invariable death within the first year of life, will not be further considered here. However, it is now known that anomalous coronary origins previously thought to be insignificant may cause sudden death in children and adolescents.

Classification of Anomalies

Eight possible congenital coronary arterial patterns of aortic origin have been described in an otherwise normal heart. They are: 1) Origin of both coronary arteries from the right aortic sinus, 2) Origin of the left anterior descending from the right aortic sinus, 3) Origin of both coronary arteries from the left aortic sinus, 4) Origin of both coronary arteries from the posterior aortic sinus, 5) Origin of the left circumflex from the right aortic sinus, 6) Origin of the right coronary from the posterior aortic sinus, 7) Origin of the left main from the posterior aortic sinus, 8) Separate ostia of the left circumflex and left anterior descending arteries in the left aortic sinus.

Only the first two of these patterns, origin of both coronary arteries from the right aortic sinus and origin of the left anterior descending from the right aortic sinus, have been associated with an increased risk of sudden cardiac death.

Incidence

Anomalous coronary origins are uncommon and most of these lesions do represent an incidental finding that may be easily overlooked at the time of autopsy in patients dying from unrelated reasons. The true incidence in the general population is unclear, but data has been accumulated from both autopsy and arteriographic series. The incidence of congenital coronary artery anomalies found during a series of 18,950 consecutive autopsies was found to be 0.3%. Incidence rates derived from coronary artery arteriographic literature are somewhat higher with a range between 0.6% and 1.55%. The most frequently encountered anomaly is the left circumflex artery arising from the right coronary artery, representing approximately 76% of the lesions in one review of the literature. Fortunately, there is no evidence of a functional significance to this particular anomaly. Within the largest arteriographic series of 38,703 patients, an ectopic origin of the left main artery from the right aortic sinus, such as in the case report described here, comprised 1.5% of the identified coronary anomalies. This uncommon lesion can be further classified based upon the course of the artery after its origin: between the aorta and pulmonary trunk, anterior to the pulmonary trunk, or posterior to the aorta. The course between the aorta and pulmonary artery is most common and also seems to be associated with the highest risk of sudden death. There seems to be a striking predilection for this anomaly in males with one reported M:F ratio of 43:5.

Pathophysiology

It is widely believed that most anomalous coronary artery origins do not cause any problems. However, a few lead to ischemic conditions with subsequent infarction, arrhythmia, and sudden death. Different mechanisms may be involved in a fatal outcome depending on the specific nature of the anomaly:

1) Instead of arising perpendicularly to the aorta, the anomalous origin may necessitate an oblique angle that is prone to compressive occlusion.

2) The anomalous artery origin may result in a bulge of endovascular tissue that acts as a pseudovalve.

3) The meandering and relatively unfastened course of the anomalous artery may render it prone to “kinking” or spasm.

4) The course of the anomalous vessel either around, or especially between, the pulmonary artery and aorta render it markedly susceptible to compressive forces.

Regardless of the mechanism, it is presumed that in certain instances of increased demand, such as strenuous exercise, the ability of the anomalous vessel to provide adequate perfusion to the heart is compromised to the point that ischemic consequences follow. This may result in an acute episode of sudden death or in cumulative damage from repeated smaller ischemic attacks. In the case presented here, the concurrent presence of acute bronchopneumonia likely exacerbated the consequences of the underlying congenital cardiac lesion.

Clinical Considerations

Most cases of symptomatic coronary artery anomalies are unsuspected and are diagnosed only at autopsy after a sudden, catastrophic event. However, many of the reported cases do share a history of past episodes of syncope or angina pectoris that occurred during or immediately after a period of exercise. Thus, although rare, it may be prudent to attempt to rule out an anomalous coronary artery origin in any child, especially male, who suffers a loss of consciousness or complains of chest pain in exercise situations without any other apparent etiology. To this end, echocardiography may sometimes identify the coronary abnormalities. However, coronary arteriography is the “gold standard” for making the diagnosis and should be utilized if an anomaly is suspected and echocardiography cannot rule it out. The demonstration of an anomalous left coronary artery origin, especially if arising from the right aortic sinus and coursing between the great vessels, in a symptomatic patient is an indication for aortocoronary bypass grafting.

In addition to the possibility of sudden death that anomalous coronary origins pose, there are angiographic and surgical considerations. An aberrantly arising artery may cause difficulty in simply finding the vessel angiographically and be a source of error in interpreting the course of the coronary arteries. An unexpected location of a coronary artery may also cause problems during cardiac surgery. Accidental transection of the left anterior descending artery, anomalously arising from the right coronary, during repair of tetralogy of Fallot has been noted.

Summary

Congenital anomalies of coronary artery origins in otherwise normal hearts, although uncommon, may carry a considerable risk of sudden death, especially in young males. Therefore, a high index of

suspicion is warranted in order to rule out this condition, which is often not diagnosed until the time of autopsy.

References:

Neufeld HN, Schneeweiss A. Coronary Artery Disease in Infants and Children. Philadelphia: Lea and Febiger; 1983, pp. 65-77.

Cheitlin MD. Coronary Arterial Anomalies. Clinical and Angiographic Aspects. In: Virmani R, Forman MB, editors. Nonatherosclerotic Heart Disease. New York: Raven Press; 1989, pp. 125-134.

Virmani R, Rogan K, Cheitlin MD. Congenital Coronary Anomalies: Pathologic Aspects. In: Virmani R, Forman MB, editors. Nonatherosclerotic Heart Disease. New York: Raven Press; 1989, pp. 153-167.

The information and opinions stated in the *Pediatric News* are the opinions of the authors and in no way reflect official policy or medical opinion of the United States Army or any other government agency.

John Baker, M.D.
Editor, *Pediatric News*
Department of Pediatrics
San Antonio Military Pediatric Center
jabaker@texas.net