PEDIATRIC NEWS

San Antonio Military Pediatric Center

Wilford Hall Air Force Medical Center
Brooke Army Medical Center
Darnall Army Community Hospital
www.sampc.amedd.army.mil

August 2004 *Volume 11 Number 4*

Housestaff Puzzler

Brett Nishikawa PL II Capt MC
San Antonio Military Pediatric Center

The on-call pediatric team was called to attend a delivery by a 28-year-old G3P1011 at 37 weeks EGA undergoing routine C-section due to maternal cerebral palsy. She had received two doses of beta-methasone prior to delivery. Prenatal labs were all reassuring. A baby girl was delivered uneventfully and given to the pediatric team vigorous and crying. Apgars were 8 and 9. Initial evaluation of the infant revealed a transverse violaceous lesion along the circumference of the left forearm. Perfusion to the left hand was adequate with a brisk (<2 sec) cap refill, but grasp reflex was notably asymmetric with markedly decreased left-hand strength and nearly absent spontaneous movement of the left arm. No other lesions or anomalies were noted on examination. Serial examinations of the infant over the next 12 hours revealed little change except a gradually more violaceous appearance to the lesion. However, over the next day the arm became more edematous. Orthopedics was consulted, examined the patient and arranged for

Continued on page 4

In this edition

Housestaff Puzzler 1
The Spectrum of Chest Wall Deformities 1
Retinopathy of Prematurity 1

The Spectrum of Chest Wall Deformities

Christopher P. Coppola MD
MAJ,USAF,MC
Staff Pediatric Surgeon
Wilford Hall Medical Center

Introduction

The spectrum of chest wall deformities ranges from cosmetically annoying to crippling. Although defects can be categorized into diagnoses, each chest is unique. These diagnoses are pectus excavatum (funnel chest) pectus carinatum (pigeon chest) and chest wall deficiencies. Age and severity at presentation vary and direct treatment. In extreme cases, physiologic impairment can be quantified, but for the vast majority, the psychosocial effects of the cosmetic nature of the defect impacts patients' lives the most.

Pectus Excavatum

The most common chest wall deformity I treat is pectus excavatum, which occurs in one in 400 births. **(Figure 1)**

Continued on page 2

Retinopathy of Prematurity

Sandy Roberts, Lt Col, USAF, MC
Pediatric Ophthalmologist
Wilford Hall Medical Center

Another busy day in clinic, it's lunchtime and you find yourself examining J.D. He's a one-year-old male, prior 26-week premie who weighed 900 g at birth. His mother is concerned because his eyes seem to wander a lot and they appear crossed on his most recent baby picture.

Continued on page 6

Continued from page 1

It is most commonly present in birth and is manifest as a slowly progressive deformity of the chest. Repair is best delayed until puberty for two reasons: early repair can result in a restrictive scarring of the chest wall and the defect may recur.

The prevailing theory to explain development of this deformity is disorganized growth of the costal cartilages. As the cartilage of each rib elongates, excessive growth forces the sternum to buckle inward. Sometimes the plane of the sternum will tilt such that either the right or left side lies deeper within the chest.

Physiologic symptoms do not occur in all patients, but usually mild. Patients can have a dull relapsing ache exacerbated by exercise. Pulmonary function deficiencies as well as decreased endurance can be present. This is best elicited by asking, "When playing with friends, do you get short of breath before anyone else?" Less commonly, patients can have compression or displacement of the heart resulting in palpitations, mitral valve prolapse or fainting spells.

Most patients will not have an associated syndrome but the defect is more common in Marfan's syndrome, Ehler-Danlos syndrome and scoliosis. It is essential to identify patients with Marfan's syndrome and find any aneurysm of the aortic root as this manifestation impacts safety of surgery and participation in sports. Genetic testing to identify Marfan's syndrome is available. Marfan's patients tend to have a more severe chest wall deformity. Patients should be examined for scoliosis, which is present in 15%, and have it quantified with roentgenography if present.

The most significant effects, by far, are the psychosocial anguish that this deformity causes young patients in their interactions with peers. They commonly hide it from family and friends and have been aware of it for years before parents discover it. Changes in behavior are decreased participation in swimming, sports, exercise, outdoors activity, showering after gym class and other activities associated with being shirtless. You would think that this would affect males exclusively, but anxieties I have heard from young women with pectus excavatum include avoidance of swimming without a shirt and inability to find a bra that fits without asymmetry or a V-shaped gap between the sternum and the fabric. These experiences will not be voiced unless you elicit them. I will routinely ask every patient "have you been teased and what have people said to you?" One patient expressed suicidal ideation caused by his deformity. These complaints make it impossible to pass off surgical correction as merely cosmetic. In the absence of any major cardiac or pulmonary symptom, the patient's desire for correction and motivation to undergo the discomfort are the most relevant indicators for repair.

Evaluation includes chest roentgenography, computed tomography, echocardiography and pulmonary function testing, preferable under exercise conditions. **(Figure 2)**

(Figure 2 Pectus excavatum computed tomography)

Many patients will have only subtle changes in cardiac or pulmonary function. An objective measurement of severity is the Haller index. It is computed by dividing transverse thoracic diameter by anterior-posterior diameter between sternum and vertebra on chest tomography. A normal value is 2.5, and a Haller index of greater than 3.25 represents a severe deformity for which surgery should be recommended.

Non-operative therapy is essentially useless and consists of efforts to improve posture and pectoral muscle development. Asymptomatic patients who opt to "live with it" can expect some progression during the years of puberty and stabilization of the chest wall when growth is complete. When I have encountered families where parents are disturbed by the deformity but the child can shrug it off, I will offer to reevaluate semi-annually. After a few visits the parents will often accept the child's confidence and stop worrying about the deformity.

The two options for surgical repair are the "Ravitch" or open repair and the "Nuss" or thoracoscopic repair. (Molik) Both rely on a bar or strut to support the corrected sternum. In the Ravitch repair, an incision is made on the chest; the pectoral muscles are stripped away and pushed to the sides, and the overgrown costal cartilages of ribs four through eight are painstakingly resected so that the sternum is destabilized. The sternum is then fixed in a level, non-depressed position with a metal bar or pin. This support occasionally requires removal for movement or pain. Removal should be delayed at least a year to allow the chest wall to stabilize. As you can imagine, there is a degree of pain associated with the procedure and a period of limited activity is required.

In the Nuss repair, a semicircular bar in the shape and dimension of

side effects. Both therapies work by destroying a small part of the retina, thus reducing the need for oxygen and abnormal blood vessel growth. It may also thin the retina allowing more oxygen to diffuse into the retina.

Most cases of advanced disease (stage 3) regress or improve with laser therapy; some eyes still progress to develop a retina detachment (stage 4 and 5). If a detachment of the retina occurs, extensive retina surgery may be required. It's important to note that anatomical reattachment is achieved in only about 60% of eyes with retinal detachment secondary to ROP and a much smaller number recover vision in these eyes. Even with current early intervention, laser therapy, and retinal surgery, many hundreds of babies each year are blinded by ROP in the United States.

Although ROP regresses in most cases, sequelae of advanced disease (stage 3) can affect a child's visual development beyond the newborn period. J.D.'s presentation of crossed eyes or strabismus is another complication. Strabismus is the crossing in or turning out of an eye. This may occur from the loss of vision (Amblyopia) in one eye or be related to the large refractive differences between the eyes. Both cataract and corneal problems can also develop. Glaucoma and retina detachments may develop early or later in life as a complication of ROP. In patients who experience significant visual loss, nystagmus, a rapid fluttering of the eyes, can also occur.

Therefore, infants and children like J.D. with a history of prematurity and ROP require frequent (usually every 6 months) scheduled periodic ophthalmic examinations after discharge from the hospital. Initial follow-up for J.D. with an ophthalmologist should have been arranged prior to his discharge from the NICU. Long-term, patients like J.D. with a history of ROP require at least an annual eye exam until adulthood.

References

1. Terry TL. Extreme prematurity and fibroblastic overgrowth of persistent vascular sheath behind each crystalline lens: I. Preliminary report. Am J Ophthalmol 1942;25:203-204.
2. Committee for the Classification of Retinopathy of Prematurity. An international classification of retinopathy of prematurity. Arch Ophthalmol 1984;106:471-479.
3. The STOP-ROP Multicenter Study Group. Supplemental therapeutic oxygen for prethreshold retinopathy of prematurity (STOP-ROP), a randomized, controlled trial: I. Primary outcomes. Pediatrics 2000;105:295-310.
4. Recchia FM, Capone Jr A. Contemporary understanding and management of retinopathy of prematurity. Retina 2004;24:283-292.
5. Windsor RL, et al. Understanding Retinopathy of Prematurity. Vision Enhancement Journal
6. Pediatric Ophthalmology and Strabismus. Basic and Clinical Science Course. Section 6 2002-03;301-329.

The information and opinions stated in the *Pediatric News* are the opinions of the authors and in no way reflect official policy or medical opinion of the United States Army or any other government agency.

John Baker, M.D.
Editor, *Pediatric News*
Department of Pediatrics
San Antonio Uniformed Services Pediatrics
jbaker29@satx.rr.com

Continued from page 1

In premature infants with ROP, the normal growth of blood vessels stops. It is theorized that the area without adequate blood supply emits a chemical trigger to stimulate growth of the abnormal vessels. These vessels lead to a formation of a ring of scar tissue attached to both the retina and the vitreous gel that fills the center of our eyes. As the scar contracts, it may pull on the retinal creating a retinal detachment.

Risk Factors

J.D.'s birth weight (900 g) and his prematurity (26 weeks) are the most significant predictors of him developing ROP. In the multicenter trial of cryotherapy for ROP (CRYO-ROP Study), 37% of infants weighing less than 750 grams developed severe (stage 3, see figure 1) ROP, whereas only 21.9 % of those weighing 750-999 g (J.D.) and 8.5% of those weighing 1000-1250 g did so. It's also important to note that ROP is rare in infants with a birth weight greater than 2000 grams.

Our understanding of ROP is changing. In 1952, Campbell theorized that the condition was caused by the use of oxygen therapy to treat the immature lungs in premature infants. Today, we realize that oxygen is not the primary factor in developing ROP. High levels of oxygen have been associated with the progression of ROP (STOP-ROP Study), but lower levels of oxygen may lead to more respiratory complications and even death in premature infants. Better oxygen level monitoring has led to better control of the oxygen given to premature infants. Today, however, there is an increase in ROP due to the fact that neonatal care advances mean more low weight premature infants are surviving.

Factors other than oxygen have also been studied. Vitamin E levels and reduction of light to premature infants have been studied. Both have resulted in conflicting results. Vitamin E is usually administered to achieve physiologic levels, however high-dose IV vitamin E usage has been associated with intraventricular hemorrhage, necrotizing enterocolitis and even death.

Reduction in light to premature infants was recently refuted in a multicenter trial as a cause of ROP, however reduction of light in nurseries to allow for better rest is a national trend in the United States. Good early prenatal care can't be underestimated as the key to the prevention of ROP, which is the best prevention of premature birth itself.

Screening

Based on the above risk factors, the Academy of Pediatrics and Ophthalmology have developed the following screening criteria for premature infants for ROP:

1. Birth weight of less than 1500 g
2. Birth weight of 1500-2000 g with an unstable clinical course.
3. Gestational age of 28 weeks or less

The examination should be performed by a retinal specialist or ophthalmologist trained for ROP exams. The first exam should normally be performed between 4-6 weeks of chronological (postnatal) age or, alternatively, within the 31st to 33rd week of post conceptional age. Initial exams are usually not required prior to 29-30 weeks. Follow-up exams in the NICU are at 1-3 week interval depending on the degree of ROP. The median age at which eyes reached threshold disease (Figure 1) in the CRYO-ROP study was 36.9 (range 33-42) weeks post conception. This age can often coincide with the age at which the patient is transferred or discharged to home.

Classification

Ophthalmologists classification of ROP describes the disease by anatomical zones, stages of severity, and clock dial like location within the eye (See figure).

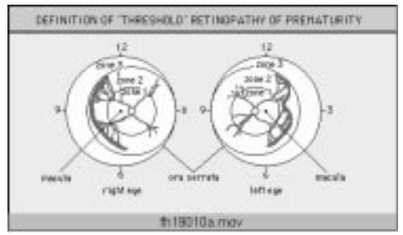

Zone 1 is the center of the retina while zone 3 is in the far peripheral retina. Stage 1 is the mildest form of ROP while Stage 5 is the most severe indicating total retinal detachment.

You will hear ophthalmologists discuss the term threshold disease. This is the point at which treatment should be administered. Threshold disease is defined as stage 3 ROP in zone 1 or 2 occupying at least five contiguous clock hours or eight noncontiguous clock hours of retina (Figure 1). For zone 2 ROP, 62 % of untreated eyes with threshold ROP went on to an untoward visual outcome (legally blind = vision less 20/200). Recent studies have revealed that threshold disease in zone 1 (posterior) yields a 90% chance of untoward outcome (rare).

Treatment, Complications, and Follow-up

Cryotherapy or the freezing of the retinal tissue has been used since the 1970s to treat ROP. Today, laser (photocoagulation) therapy is a newer treatment modality that has been shown to be as effective as cryotherapy, but with less systemic

the ideal chest wall for the child is inserted through into chest on one side and guided beneath the sternum to the opposite side with the aid of a thoracoscope. Once in place, the bar is "flipped" so that it forces the sternum forward to a normal position. After 1-2 years the bar is removed, as it will limit chest growth to the diameter of the bar. This method is faster, associated with less pain and has been shown to increase exercise tolerance. (Sigalet) After either repair patients are restricted from heavy activity or sports for two months after surgery so I try to schedule surgery for the summer to reduce interference with school and athletic activities.

Pectus Carinatum

Many of the same principles apply to pectus carinatum, which occurs about one tenth as frequently as pectus excavatum. Pathophysiology is also thought to involve disordered growth of the costal cartilages. In contrast, pectus carinatum usually presents after age 10 years and nearly always includes a tilted or distorted sternum. (Fonkalsrud) Cardiac and pulmonary effects can occur. The Haller index can be measured, calculating it at the point of greatest anterior protrusion, and averages to 1.7. **(Figure 3)**

(Figure 3: Pectus carinatum computed tomography)

Young people with pectus carinatum suffer the same anguish over their condition as those with pectus excavatum. There is the same avoidance of shirtless activities and a common behavioral response is use of bulky clothing, even in the heat of Texas, and a slumped forward posture to disguise the bulge of the lower sternum. One young man I treated would excuse himself after dinner and retire to his room, and it was months before his parents discovered that he would lie supine with a board and a stack of heavy books on his chest in an attempt to mold the deformity.

His instinct was not all wrong; one therapeutic option is to place the child in a compressive clamshell orthotic that exerts pressure on the prominent sternum. Some practitioners have reported success but discomfort, pressure sores and failure limit therapy.

The only surgical option that exists is the Ravitch repair. Variations exist; in particular, many surgeons choose not to secure the sternum with a metal strut after destabilizing it through removal of costal cartilages.

Chest wall deficiencies

The only convenient way to describe these entities is to lump them together and advise the clinician to tailor treatment to the severity and presentation in each individual. In contrast to pectus excavatum and carinatum these deformities present in infancy and are associated with more severe pulmonary insufficiency. The challenge of treating these unfortunate children has inspired the development of novel therapies such as materials to replace gaps in the chest wall and titanium ribs placed laterally to increase ventilation volume.

Poland's syndrome is a unilateral absence of layers of the chest wall. It ranges from decreased subcutaneous fat to lack of muscle, bone, skin and hand abnormalities. (Fokin) The deficient chest wall is essentially a flail chest, and constructing a support structure without eventual infection or collapse is a surgical challenge

Jeune's syndrome, or asphyxiating thoracic dystrophy of the newborn, is a puzzling entity where the ribs fail to grow properly resulting in a rigid bell-shaped thoracic cavity with a narrowed apex. In addition to the pulmonary insufficiency, which usually requires tracheostomy and prolonged ventilator support, inability to adequately clear secretions leads to pneumonia. Efforts to expand the thoracic cavity are hampered by collapse but lateral support with titanium struts has won some long-term successes. (Davis)

Jarcho-Levin syndrome or spondylothoracic dysplasia is a crab-like pattern of the ribs arising from a shortened and deformed thoracic vertebra. It is often associated with cardiac and renal anomalies. Patients have severe pulmonary deficiency and are hard-pressed to survive infancy.

In Conclusion

The spectrum of chest wall deformities comprises a varied array of abnormalities with a broad range of presentation and prognosis. It is fortunate that the more common pectus excavatum and carinatum, which are marked by a greater psychosocial morbidity than physiologic, are amenable to repair with good prognosis.

References

Molik KA, Engum SA, Rescorla FJ, et al: Pectus excavatum repair: Experience with standard and minimal invasive techniques. J Pediatr Surg 36:324-328, 2001.

Sigalet DL, Montgomery M, Harder J: Cardiopulmonary effects of closed repair of pectus excavatum. J Pediatr Surg 38:380-5, 2003

Fonkalsrud EW, Beanes S: Surgical management of pectus carinatum: 30 years' experience. World J Surg, 25:898-903, 2001

Davis JT, Long FR, Adler BH, et al: Lateral thoracic expansion for Jeune syndrome: evidence of rib healing and new bone formation. Ann Thorac Surg 77:445-448, 2004.

Fokin AA, Robicsek F: Poland's syndrome revisited. Ann Thorac Surg 74:2218-2225, 2002.

Continued from page 1

outpatient follow-up. She was discharged home to the care of her parents, with a follow-up visit scheduled in the pediatric clinic at 11 days old.

At the follow-up visit, the edema in the arm had begun to subside, and parents reported she was beginning to show movement in her left hand. On exam the left hand was notably edematous and seemingly tender, with apparent slight weakness compared to the other arm. She demonstrated minimal movement of the left shoulder and hand with markedly diminished movement of the elbow, otherwise had normal tone and normal primitive reflexes. Hematology-Oncology was consulted from the clinic. Following examination and discussion with the pediatric radiologist, the impression was that the lesion was unlikely to be a malignancy, but was concerning for a DVT causing in-utero compartment syndrome. An extensive coagulation panel (PT, PTT, thrombin time, fibrinogen, protein C, protein S, Factor V Leiden, activated protein C resistance, antithrombin III, and Factor II mutation) was recommended for the parents to assess the likelihood of an inherited coagulation disorder. Orthopedic recommendation was for an MRA looking at the arterial and venous flow in the affected arm.

Dysmorphology

A thorough understanding of dysmorphology requires a review of basic definitions. Malformation is an intrinsic anomaly resulting from an error in basic morphogenesis. A disruption is an event which affects a previously normally formed part. A deformation results from an external force altering the shape or structure of a normally differentiated part. Dysplasia is the abnormal growth, maturation, and organization of cells.

History gathering in a child with dysmorphic features should include an extensive, detailed family history. Pregnancy history is important, including details of prior pregnancies (including pregnancy loss), planning, maternal and paternal occupation and health during conception and pregnancy, substance exposure (medication, alcohol, tobacco, and drugs), maternal illness, and fetal movement. Potentially important information about perinatal events include fetal distress, polyhydramnios or oligohydramnios, and birth dimensions (weight, length, head circumference). Children beyond the neonatal period require a thorough developmental history.

In addition to obvious dysmorphic features, physical examination should strive to identify minor anomalies which may assist in diagnosis. The most common locations for such features are craniofacial (head, eyes, mouth, ears, hair), and skin (particularly hyper- or hypopigmented areas). Other areas include the xiphoid, umbilicus, hands, chest, sacrum, heels, and scrotum.

The patient's MRA showed no tumor and no evidence of continued compromise of blood flow. She was seen by Neurology, who deferred further management to Orthopedics. She was also referred for ongoing Occupational and Physical Therapy via Early Childhood Intervention. Hematology workup revealed activated protein C resistance in both parents, although neither was positive for the Factor V Leiden mutation. These results were not considered to be significant for the patient, as she demonstrated no evidence of continued hypercoagulability.

Thromboembolic Disease

The incidence of venous thromboembolism in children is estimated at 1-2 per 100,000, with peaks in the neonatal (up to 6 months) and adolescent years. The incidence in neonates is approximately 0.5 per 10,000, probably due to immature coagulation, decreased activity of anticoagulants, and decreased fibrinolytic activity. The most common risk factor for thrombosis in infants is the presence of central venous catheters. Other risk factors include perinatal asphyxia, sepsis, dehydration, and maternal diabetes. Predisposing disorders in all children include prematurity, malignancy (especially ALL), congenital heart disease, trauma, surgery, renal disease, and SLE.

The most common inherited prothrombotic disorder is a mutation in the Factor V gene (Factor V Leiden), which is carried in 3-8% of Caucasians. Factor V Leiden mutation is found in 95% of patients with activated protein C resistance. These patients demonstrate resistance to protein C, an anticoagulant factor which impairs thrombin formation. A significantly higher prevalence of the Factor V Leiden mutation is found in neonates and children with thromboembolic

disease compared with children without thrombotic disease. Thromboses may occur in arterial or venous circulation. Several conditions have been linked to thrombosis from Factor V Leiden, including porencephaly, cerebral palsy, Legg-Calve-Perthes disease, and Behçet's disease.

A mutation in the prothrombin gene at position 20210A produces elevated prothrombin levels which promotes increased thrombin formation. This mutation is the second most common genetic cause of prothrombotic events, reaching a prevalence of 4-5% in Mediterranean populations. Because of the high variability of prothrombin levels, identification of this condition requires polymerase chain reaction (PCR) testing for the specific mutation.

The patient was referred at 7 months of age for further evaluation to an orthopedic subspecialist at an outside hospital. At the time, she had increased use of her left arm, although still less than the right. She had no range of motion of the wrist, minimal thumb abduction, and some movement of fingers. It was felt the findings had most likely resulted from an amniotic band with subsequent decreased perfusion. She was seen by a hand team who opted not to intervene, given her age and her degree of clinical improvement.

Amniotic Bands

The amniotic band sequence results from free-floating strands of amnion which may be caused by disruption of the amniotic membrane, e.g. due to trauma or inflammation. These can result in malformations or disruptions depending on the time in gestation in which they occur. Malformation of the limb and body wall (limb-body wall malformation complex) is thought to be due to amniotic bands, although in some cases the etiology is believed to be disruption of local vasculature. Involvement of the body wall is thought to occur earlier in gestation than isolated limb involvement. Incidence of all amniotic bands ranges from 1 in 1200 to 1 in 15,000 live births. Severity can range from simple constriction bands transversely around a limb or digit, to constriction with distal lymphedema, to distal fusion of parts, to amputation. The nature and timing of treatment, particularly orthopedic management, varies according to the location and degree of injury.

The patient demonstrated gradual improvement with continued therapy. She has had no further significant health problems, hematologic, orthopedic, or otherwise. Use of the left arm and hand have steadily increased. She is currently meeting age appropriate developmental milestones, including gross and fine motor skills.

References

De Pablo A, Calb I, Jaimovich L. Congenital constriction bands: amniotic band syndrome. J Am Acad Dermatol 1995; 32:528-9.

Hoppe C, Matsunaga A. Pediatric thrombosis. Pediatr Clin North Am 2002; 49:1257-83.

Hunter AGW, Hall J. Medical genetics: The diagnostic approach to the child with dysmorphic signs. CMAJ 2002; 167:367-72.

Jones KL. Dysmorphology. In: Behrman RE, Kliegman RM, Jenson HB, editors. Nelson Textbook of Pediatrics. 16th ed. Philadelphia: W.B. Saunders Company; 2000. p. 535-8.

Larsen WJ. Human Embryology. New York: Churchill Livingstone; 1993.

Streif W, Andrew ME. Venous thromboembolic events in pediatric patients. Diagnosis and management. Hematol Oncol Clin North Am 1998; 12:1283-312.

Martinez-Frias ML. Body stalk defects, body wall defects, amniotic bands with and without body wall defects, and gastroschisis: comparative epidemiology. Am J Med Genet 2000; 92:13-8.

Van Heest AE. Congenital disorders of the hand and upper extremity. Pediatr Clin North Am 1996; 43:1113-33.

Continued from page 1

She does not recall hearing anything about the term Retinopathy of Prematurity (ROP), but she does remember some eye doctor "torturing" her baby with frequent eye exams during their initial NICU hospitalization. The infant has had no follow-up ophthalmic care since discharge.

This fictional patient (J.D.) encounter will be used to highlight several important issues regarding Retinopathy of Prematurity (ROP) to include an overview, risk factors, screening criteria, complications and recommended follow-up for children with a history of ROP.

What is ROP?

Retinopathy of prematurity (ROP), originally termed retrolental fibroplasia, was initially described in 1942 by Terry. ROP results from abnormal (incomplete vascularization) of the retina in premature babies. The retina is the light sensitive lining of the eye and during normal retinal development; vessels migrate from the optic disk to the periphery (ora serrata). These vessels begin to migrate at about 16 weeks of gestation and mature nasally at 36 to 41 weeks. The last twelve weeks of a normal 40-week gestation are crucial in the development of fetal eyes.